

Sindrome del cuore sinistro ipoplasico

59



Handwritten initials

Handwritten signatures

Trasposizione congenitamente corretta delle grandi arterie



Trasposizione delle grandi arterie con difetto del setto interventricolare e ostruzione tratto di efflusso ventricolare sinistro



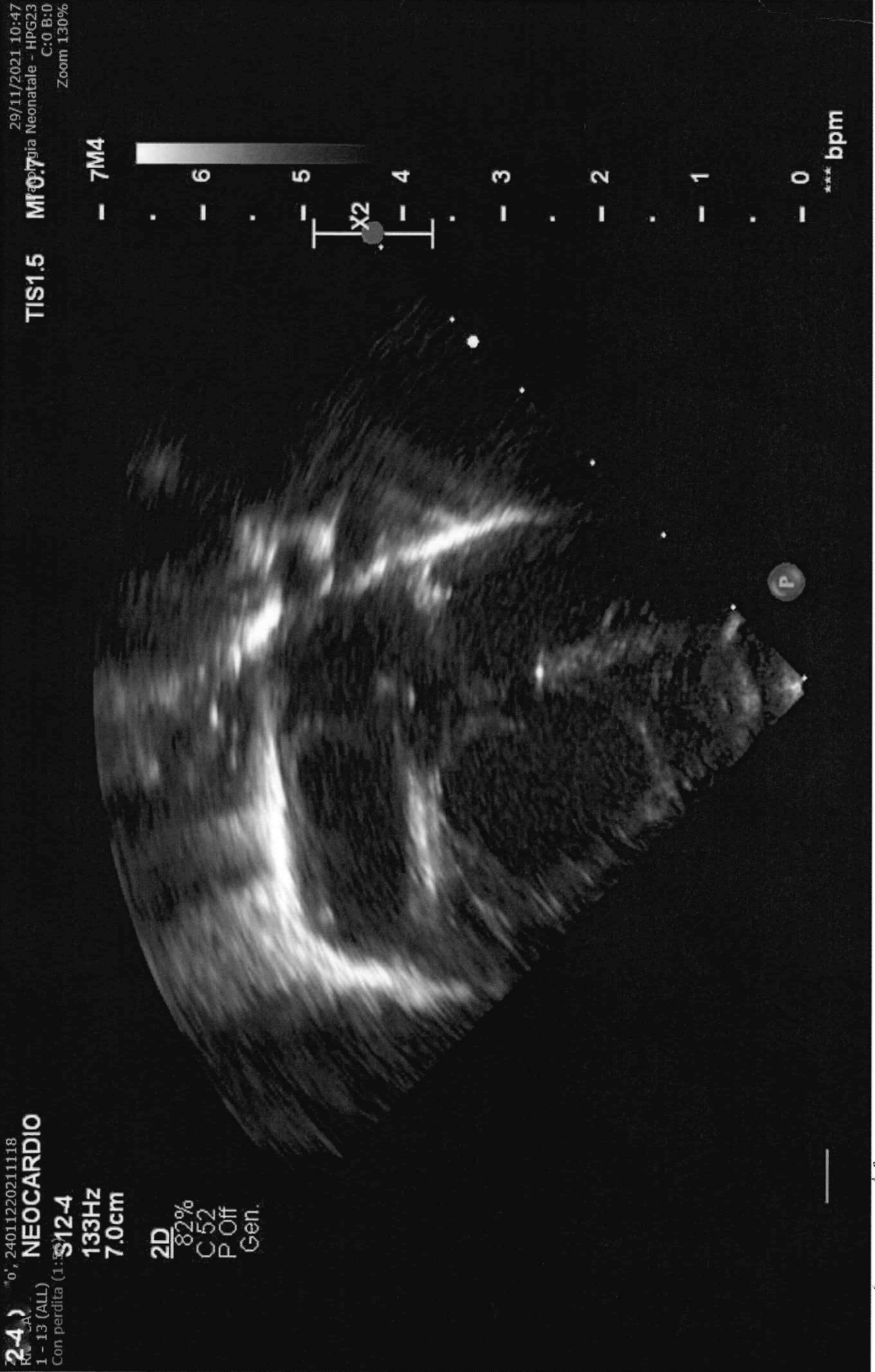
ECO COLOR DOPPLER CARDIACO



h

[Handwritten mark]

[Handwritten signature]



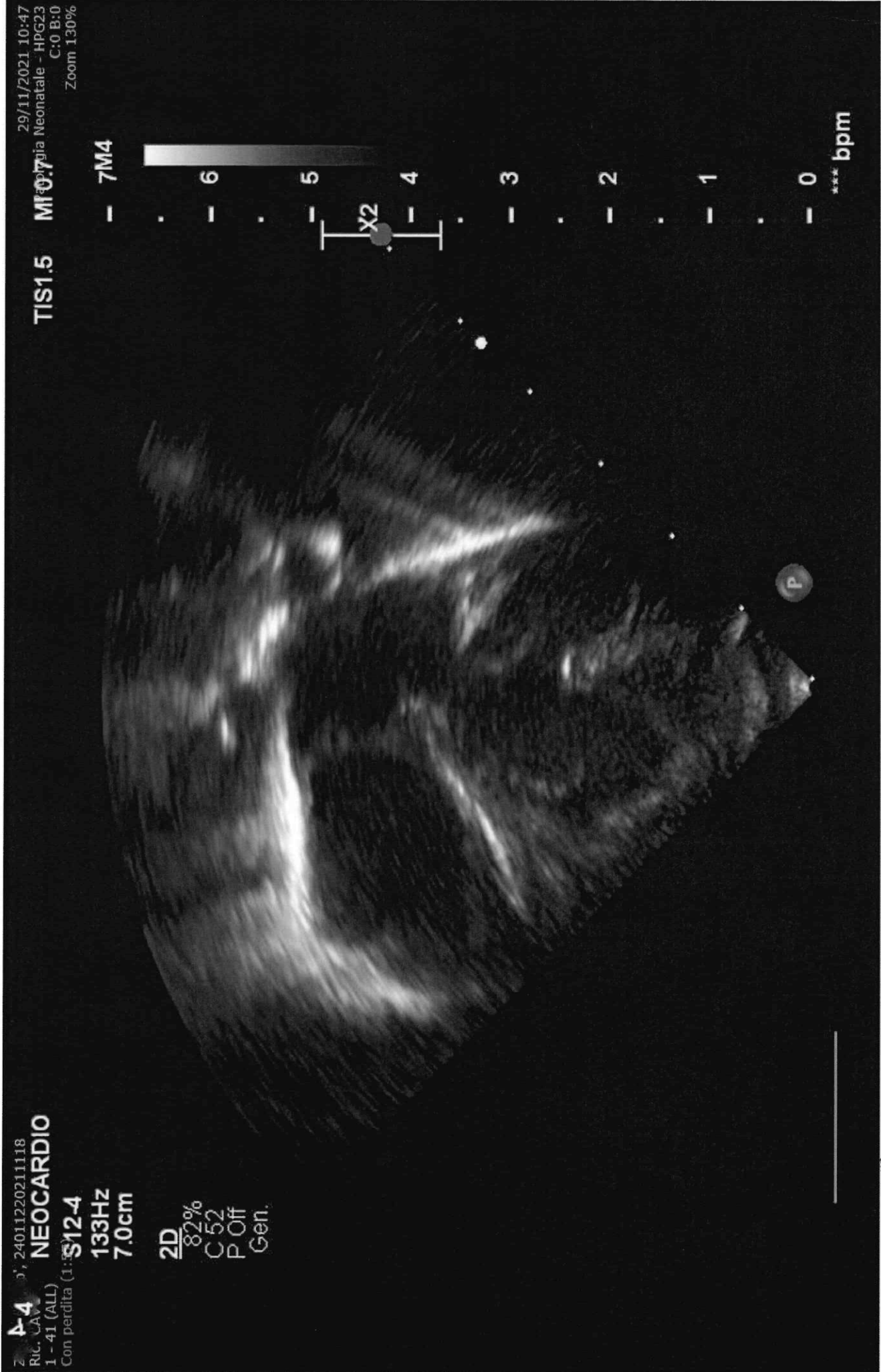
1°

(Handwritten notes and signatures)

(Signature)

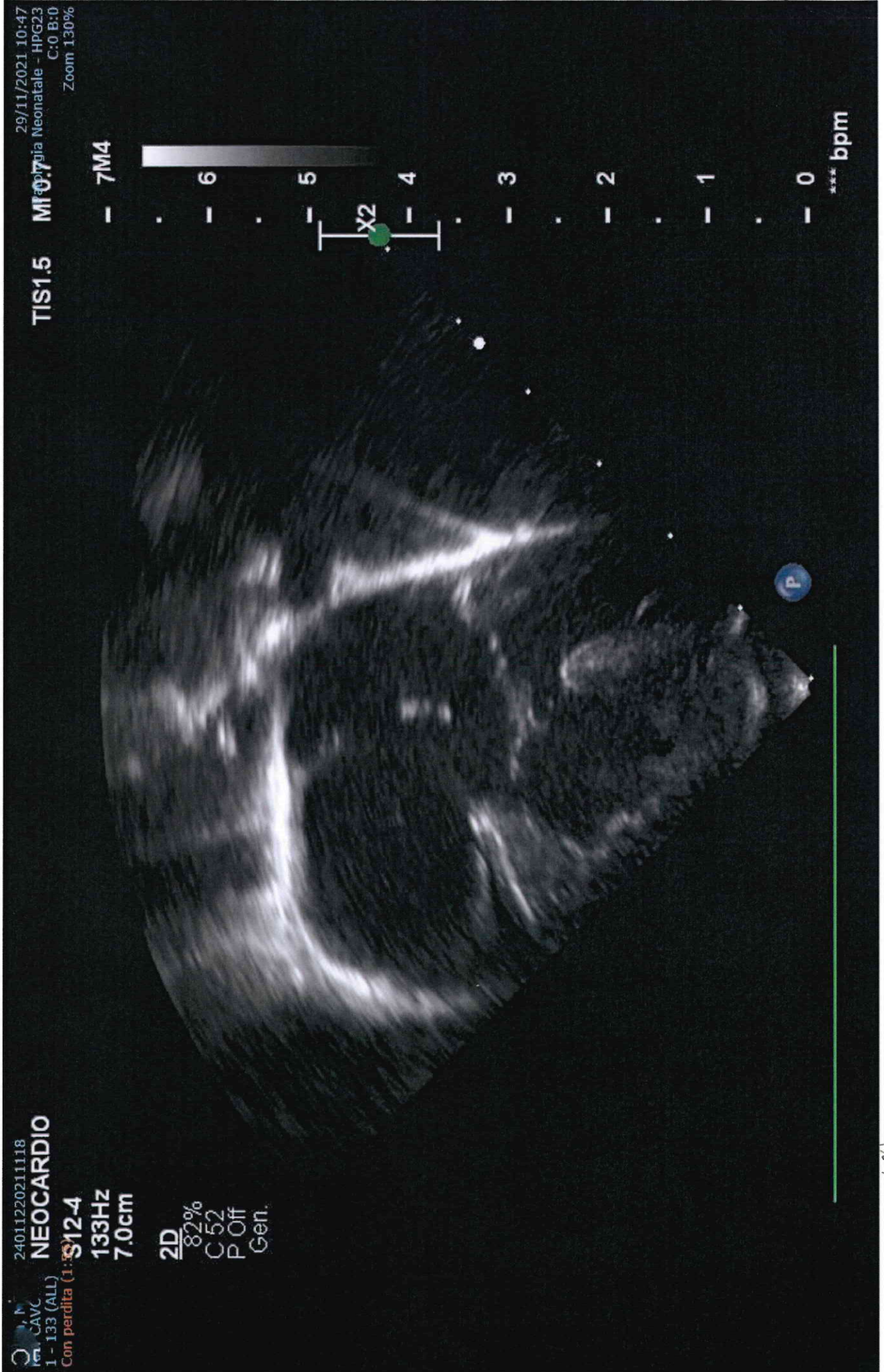
(Signature)

(Signature)

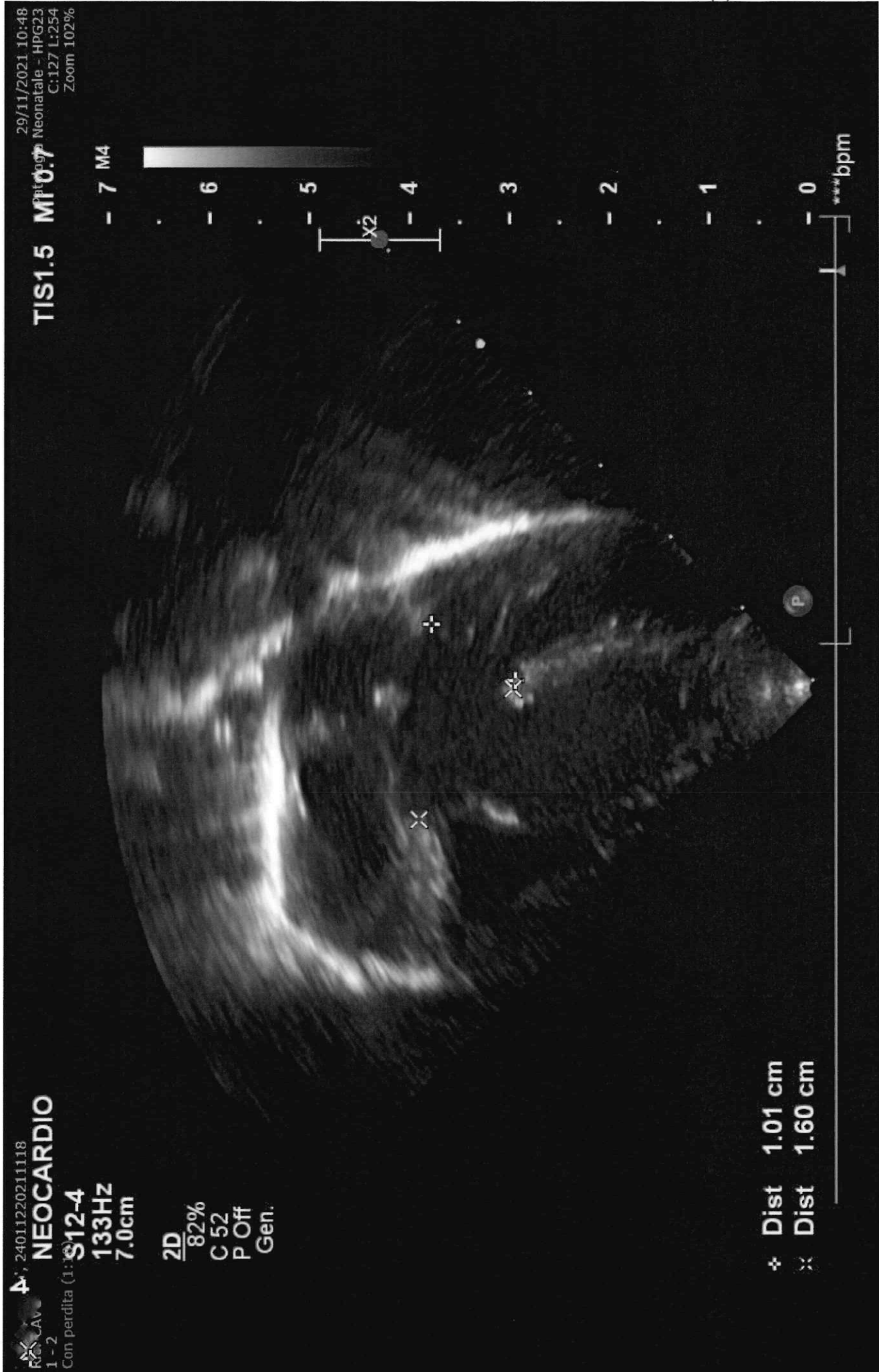


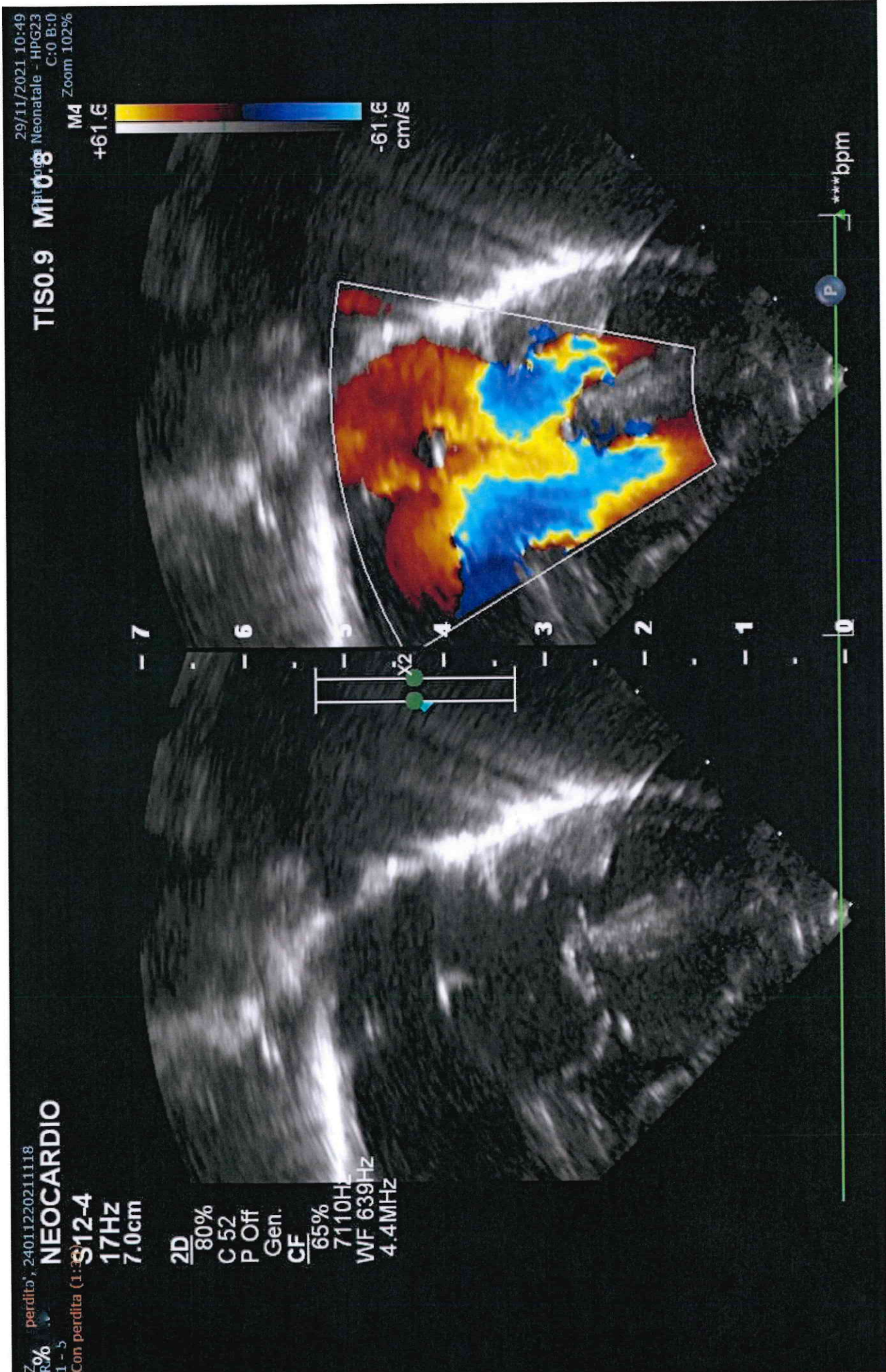
Handwritten notes and signatures:
 M P
 BY
 R

40



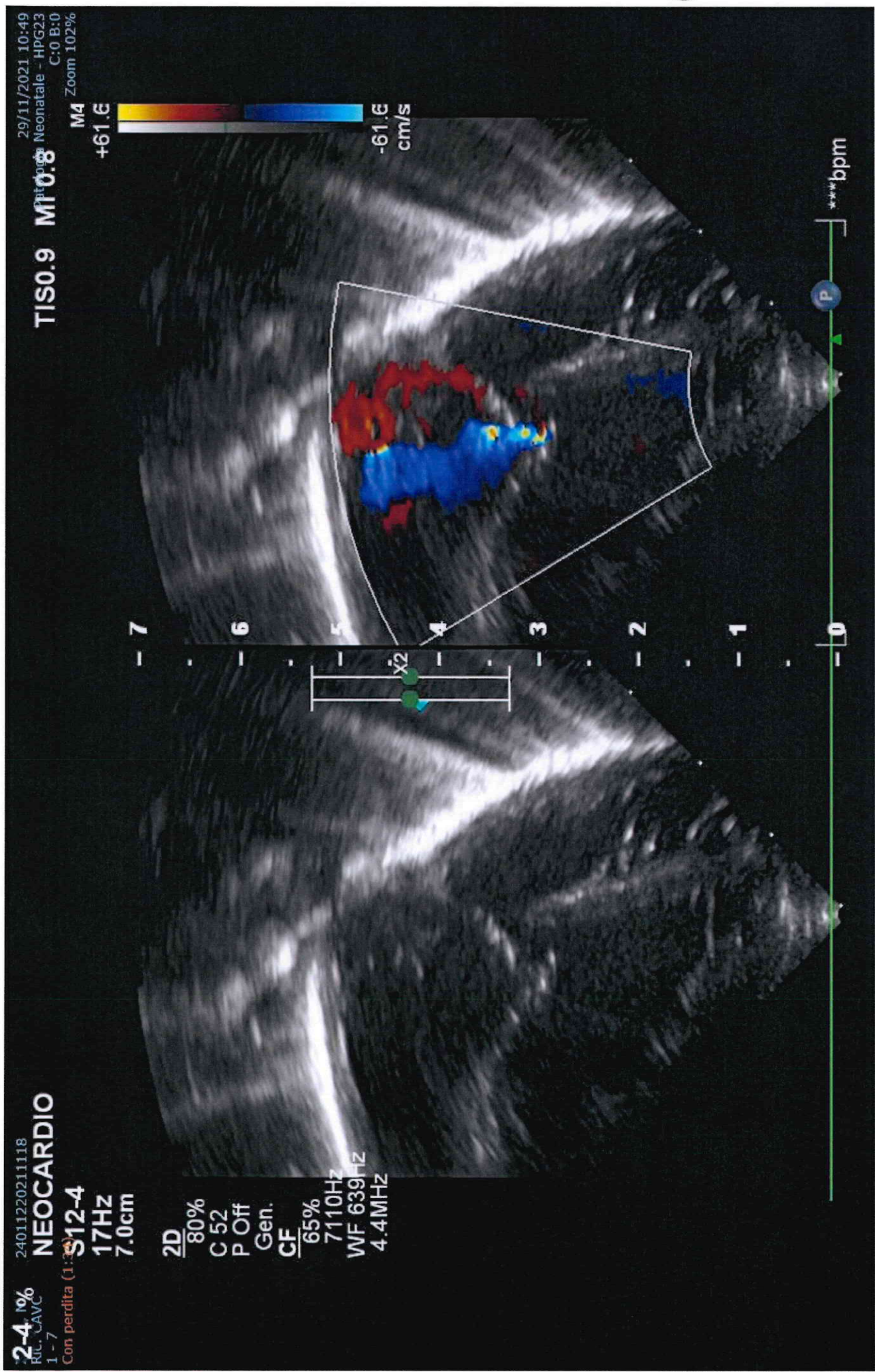
cd
te
te





5.

Handwritten signatures and initials:
 [Signature]
 [Signature]
 [Signature]



6.

[Handwritten signature]

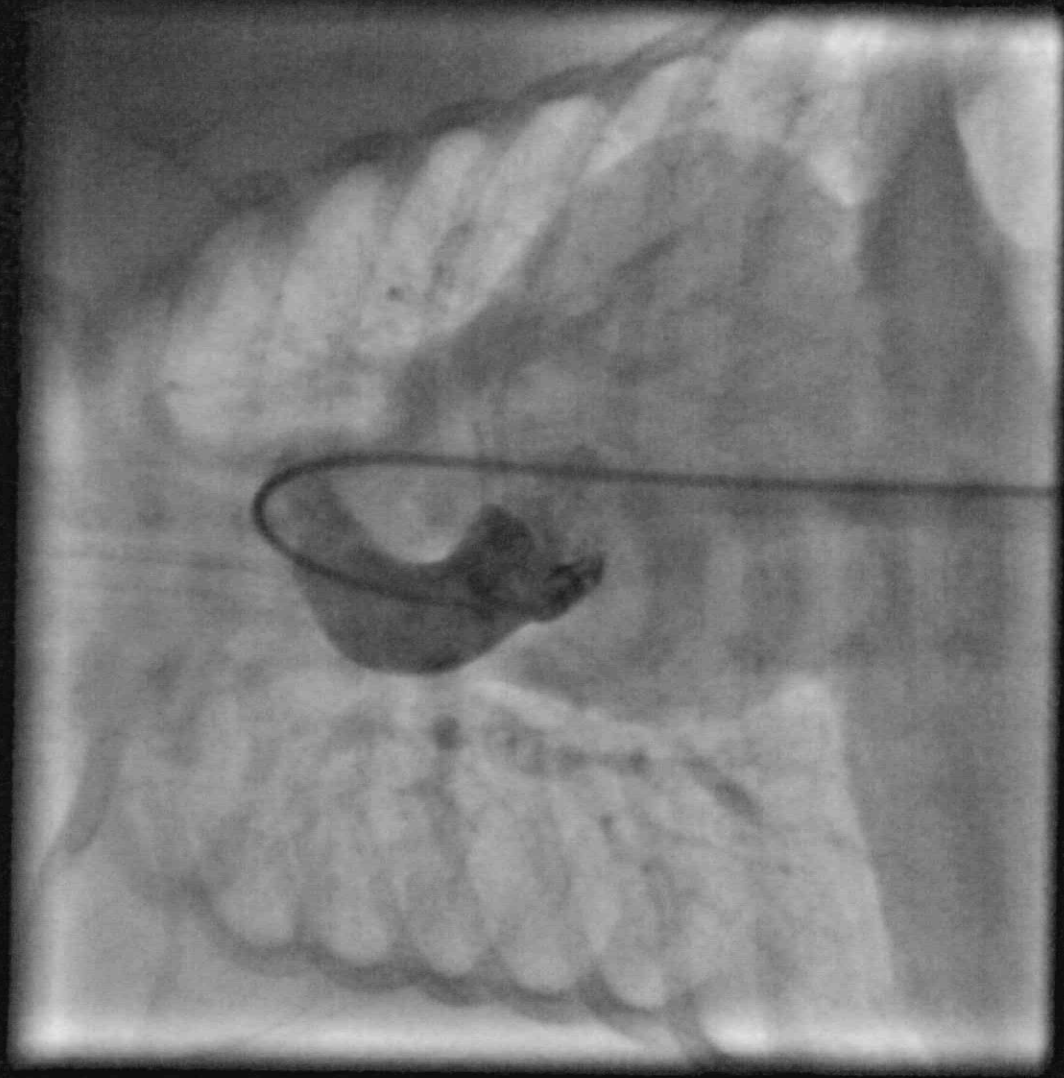
[Handwritten signature]

CATERISMO CARDIACO



[Handwritten signature]

25/05/2022 13:24
A.O. PAPA GIOVANNI XXIII BERGAMO
C:128 L:256
Zoom 152%



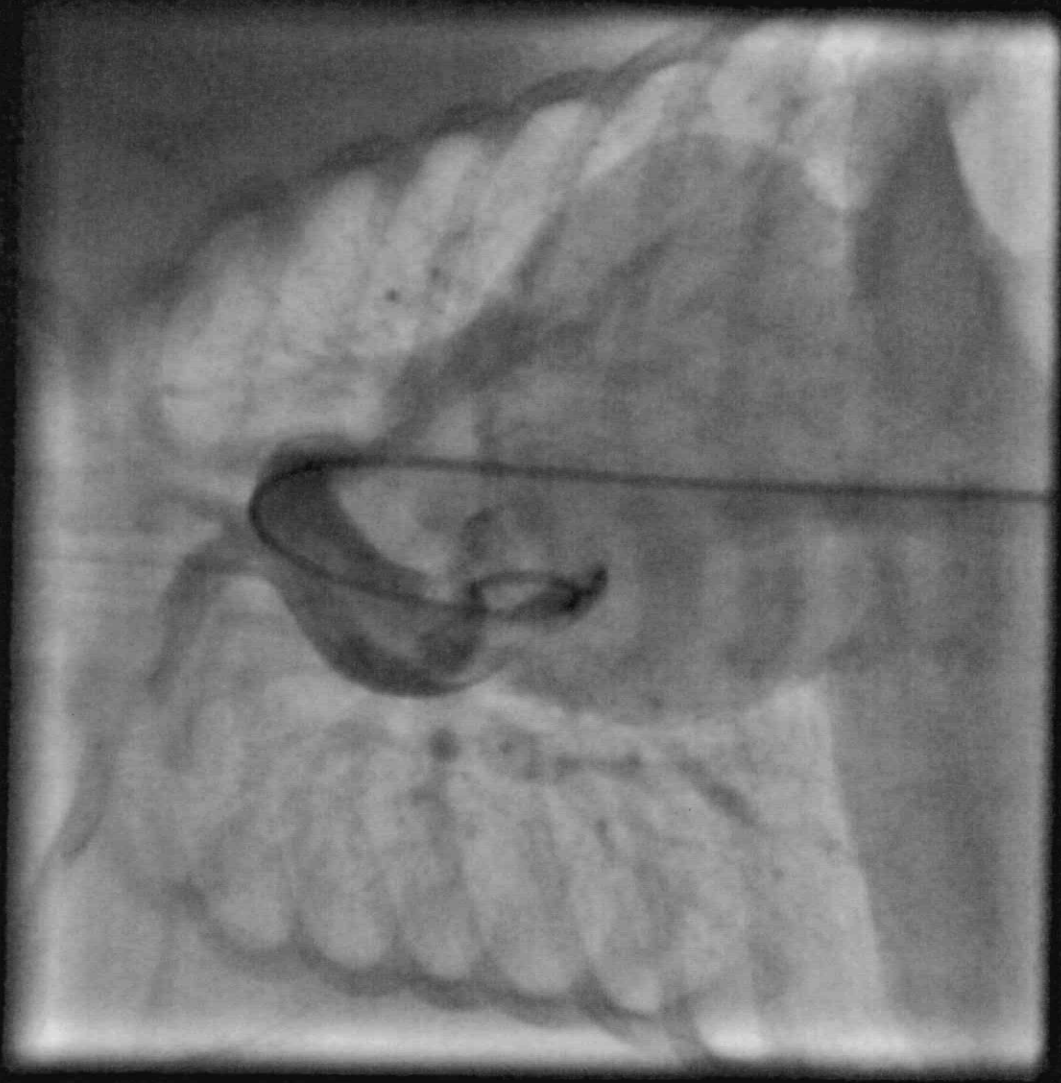
015 90120 212319150
Desc. studio: CONGENITO DIAGNOSTICO
1 - 45 (ALL)
Con perdita (1:19)

1.

[Handwritten signatures and initials]

TICO, O, OCIR (e)150
Desc. studio: CONGENITO DIAGNOSTICO
1 - 46 (ALL)
Con perdita (1:19)

25/05/2022 13:24
A.O. PAPA GIOVANNI XXIII BERGAMO
C:128 L:256
Zoom 152%

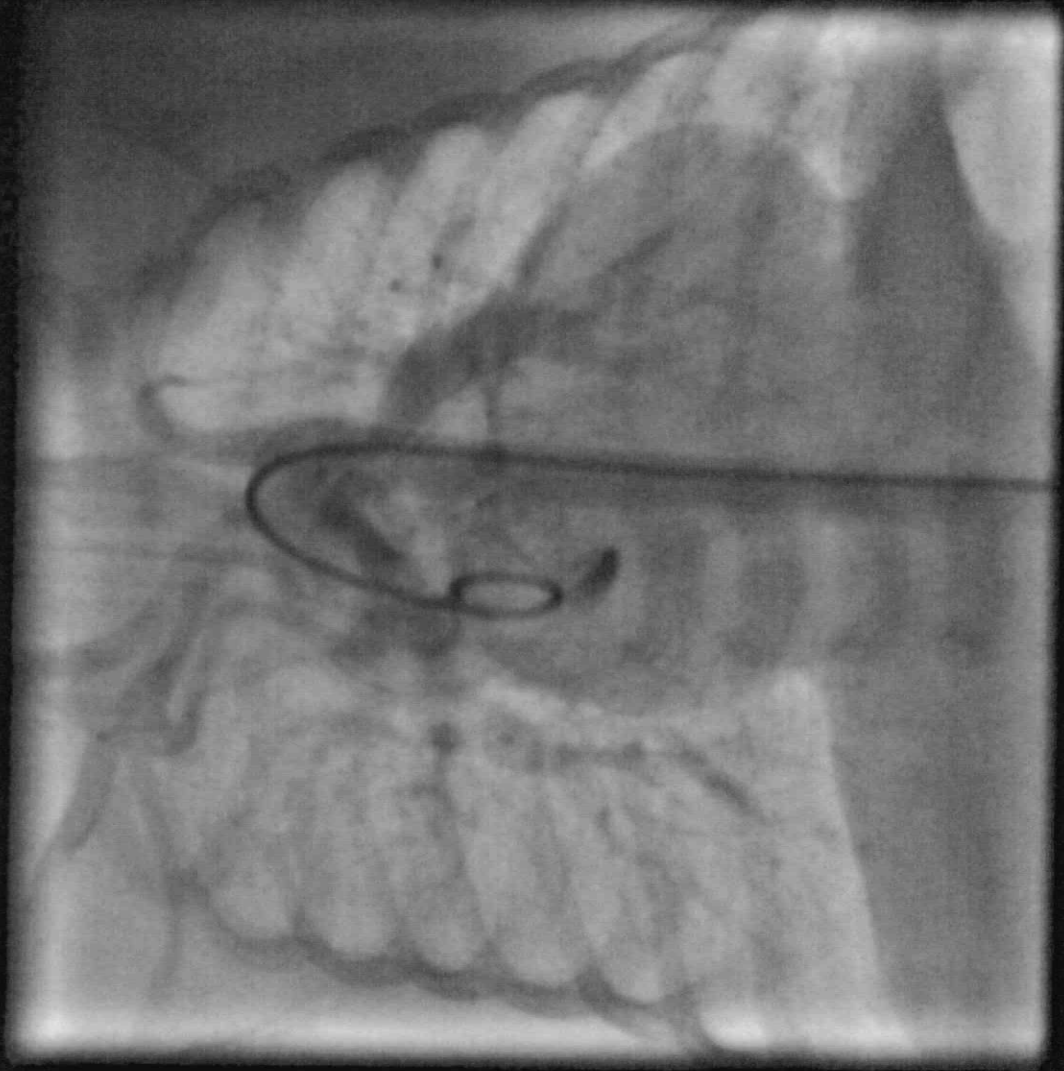


2.

Handwritten signature and initials

000120000126 (819150
1-47 (ALL)
Desc. studio: CONGENITO DIAGNOSTICO
Con perdita (1:19)

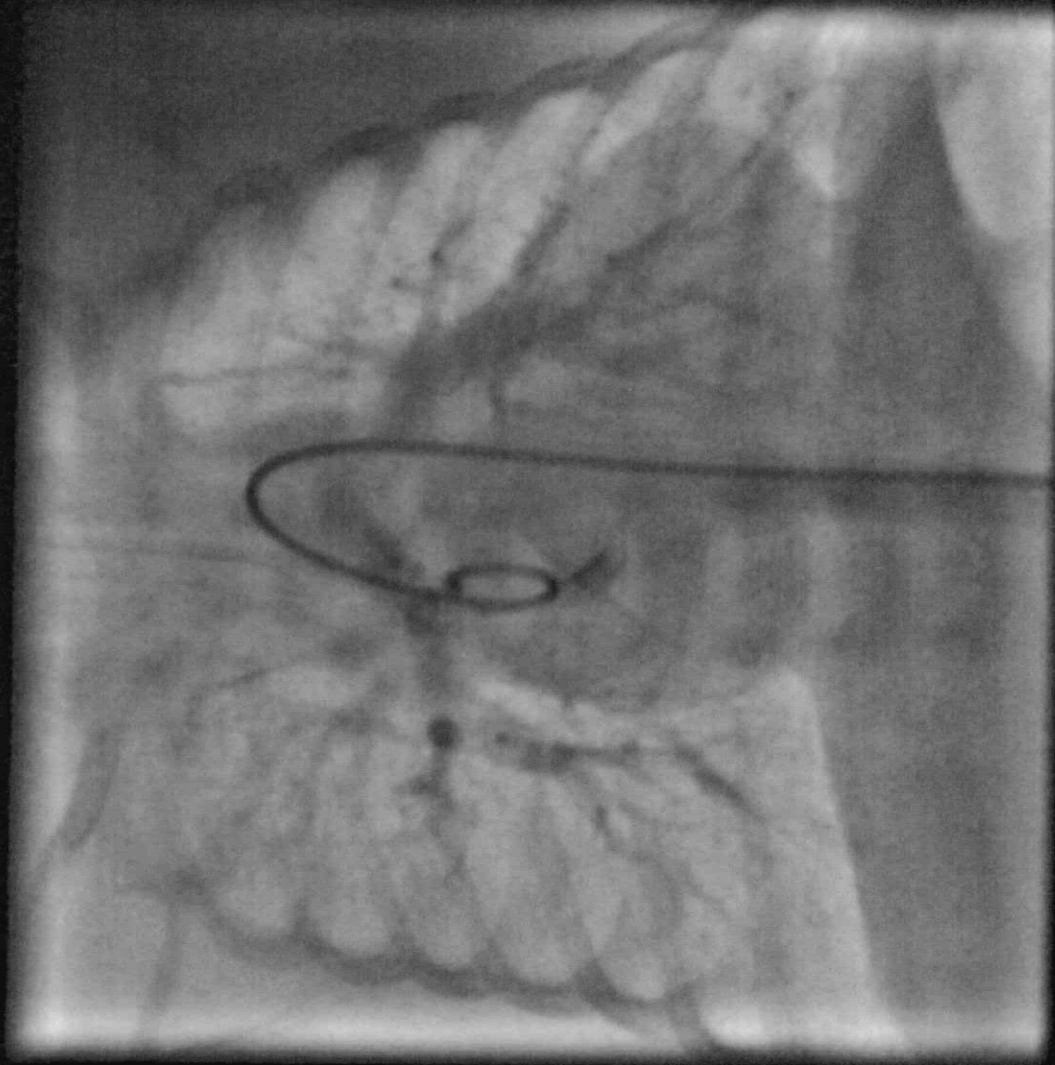
25/05/2022 13:24
A.O. PAPA GIOVANNI XXIII BERGAMO
C:128 L:256
Zoom 152%



le
[Signature]
+
[Signature]

3.

25/05/2022 13:24
A.O. PAPA GIOVANNI XXIII BERGAMO
C:128 L:256
Zoom 152%

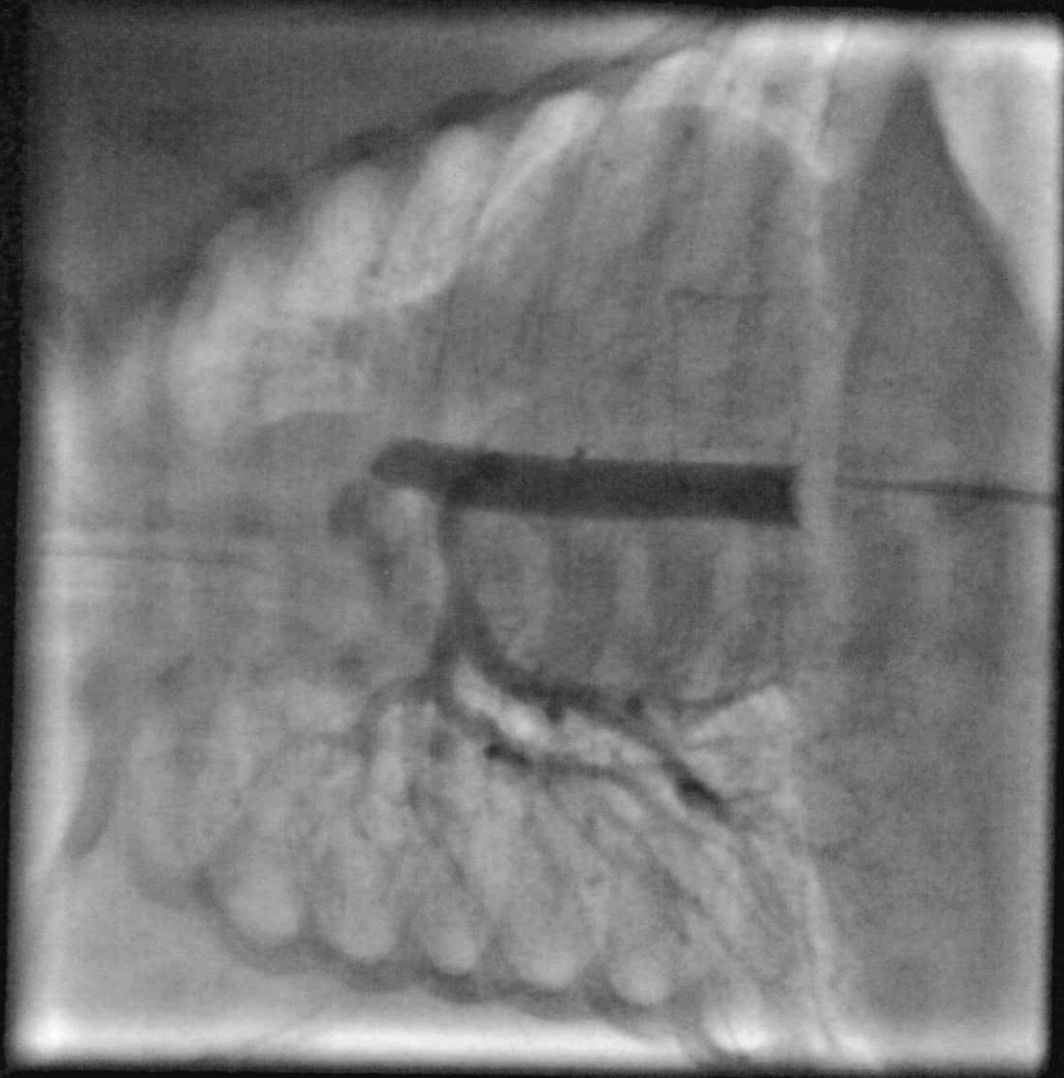


Ojetti 01:11 #2319150
C.C.: 1036/
Desc. studio: CONGEMITO DIAGNOSTICO
1 - 49 (ALL)
Con perdita (1:19)

Handwritten notes and signatures on the right side of the page, including a large signature and several smaller marks.

4.

25/05/2022 13:50
A.O. PAPA GIOVANNI XXIII BERGAMO
C:128 L:256
Zoom 152%



02105710, IGO 212319150
P.A.S. 1 - 06762
Desc. studio: CONGENITO DIAGNOSTICO
1 - 51 (ALL)
Con perdita (1:18)

Handwritten signatures and initials, including a large stylized signature and the letters 'fe'.

Cleone Luomo

ANGIO-TAC



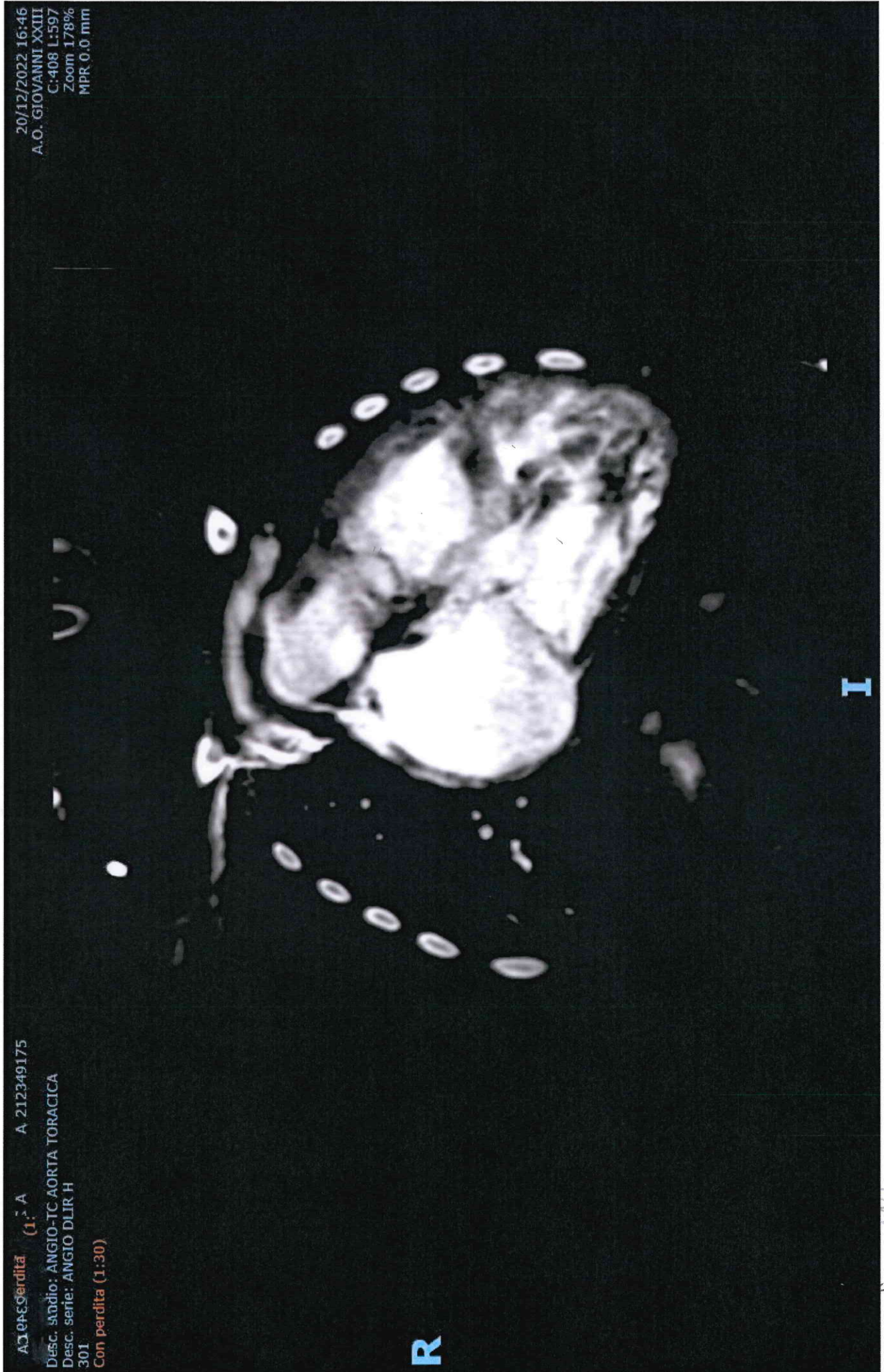re

[Handwritten signature]

[Handwritten signature]

20/12/2022 16:46
A.O. GIOVANNI XXIII
C:408 L:597
Zoom 178%
MPR 0.0 mm

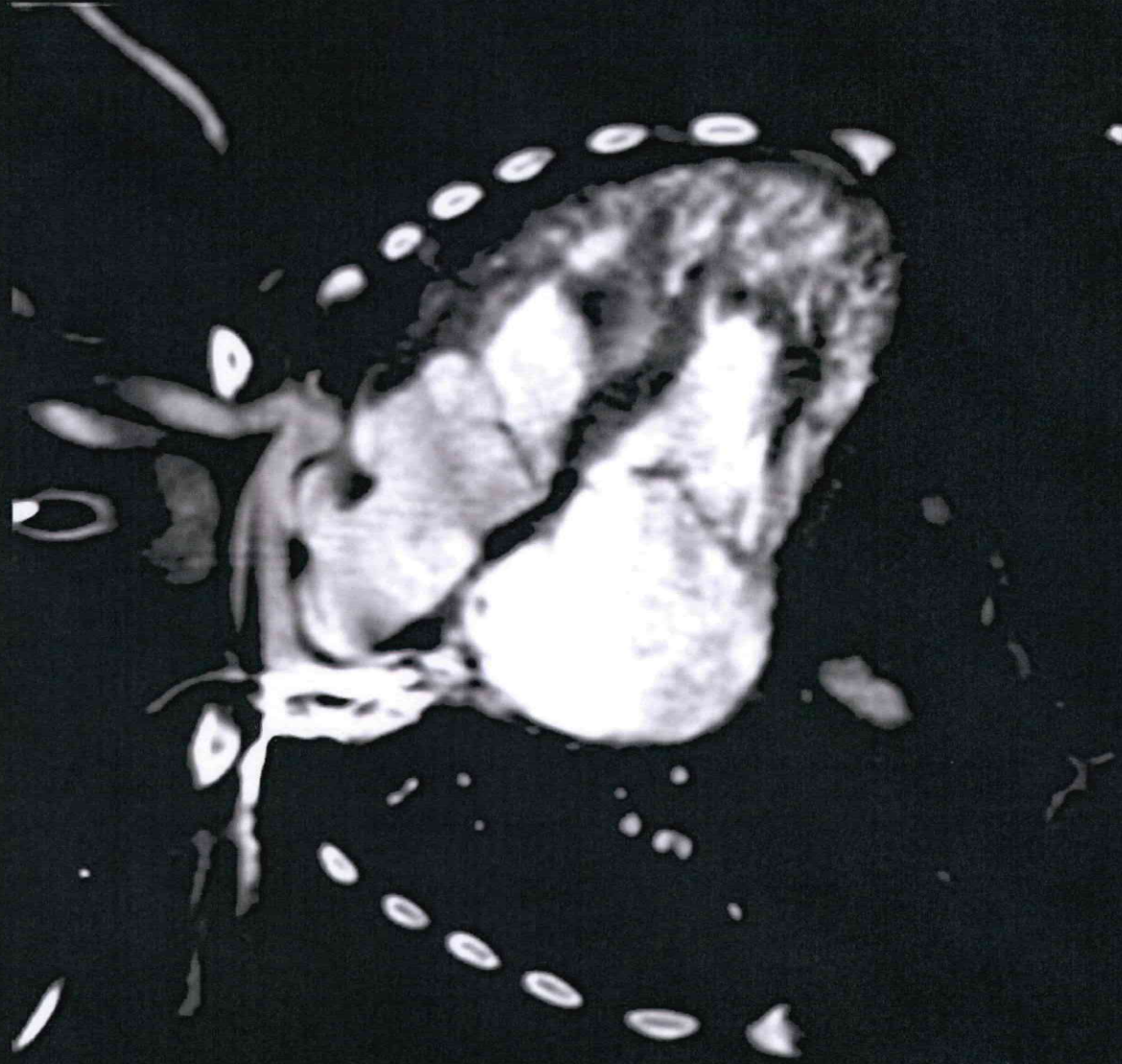
ACIEMERDITA (1,2) A A 212349175
Desc. addio: ANGIO-TC AORTA TORACICA
Desc. serie: ANGIO DLIR H
301
Con perdita (1:30)



Handwritten signature and initials.

20/12/2022 16:46
A.O. GIOVANNI XXIII
C:408 L:597
Zoom 178%
MPR 0,0 mm

uorT-00-Tior 2V1 (vs:17) 2(VS:179175
R11 0001 04
Desc. studio: ANGIO-TC AORTA TORACICA
Desc. serie: ANGIO DLIR H
301
Con perdita (1:27)

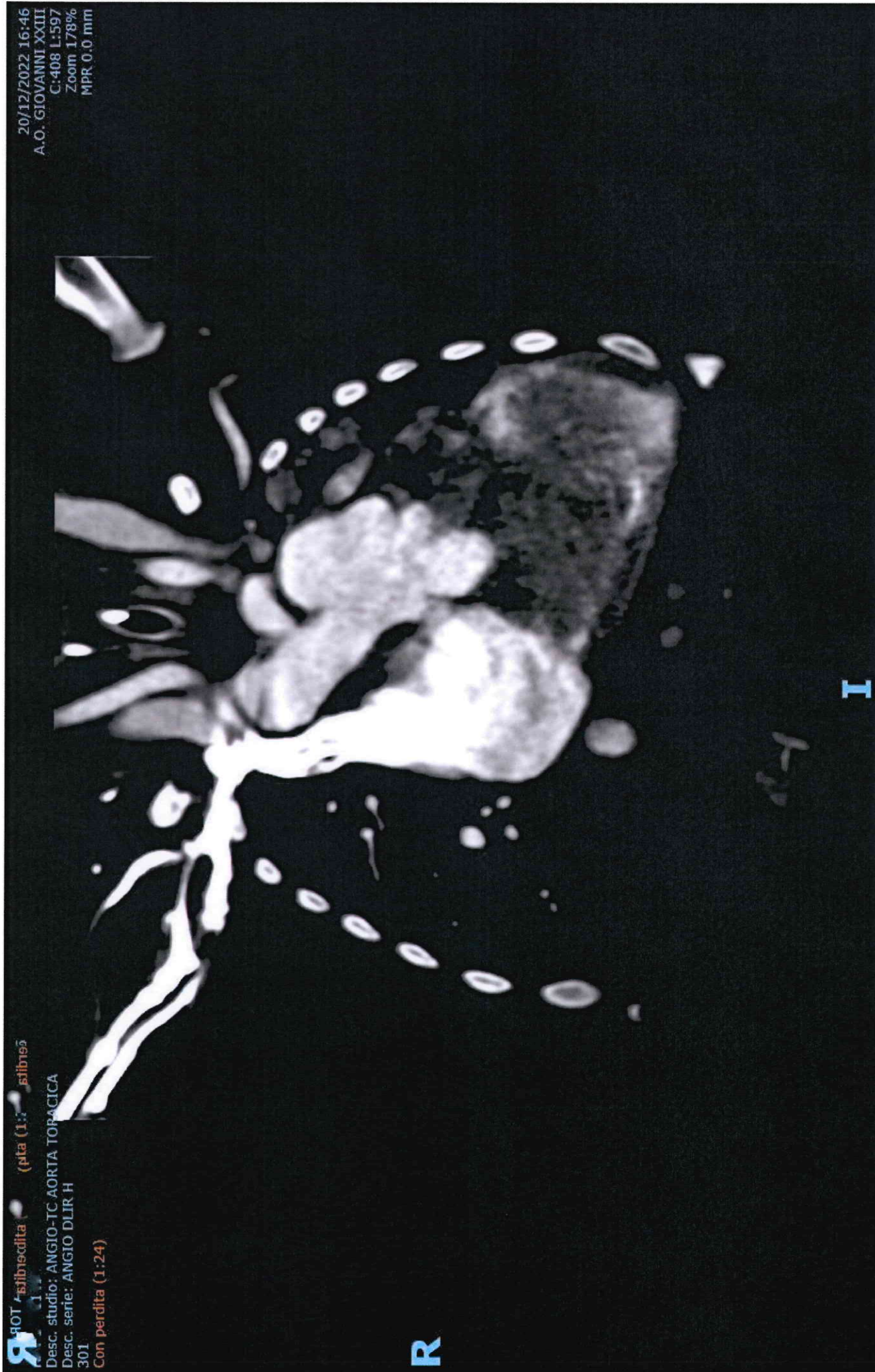


R

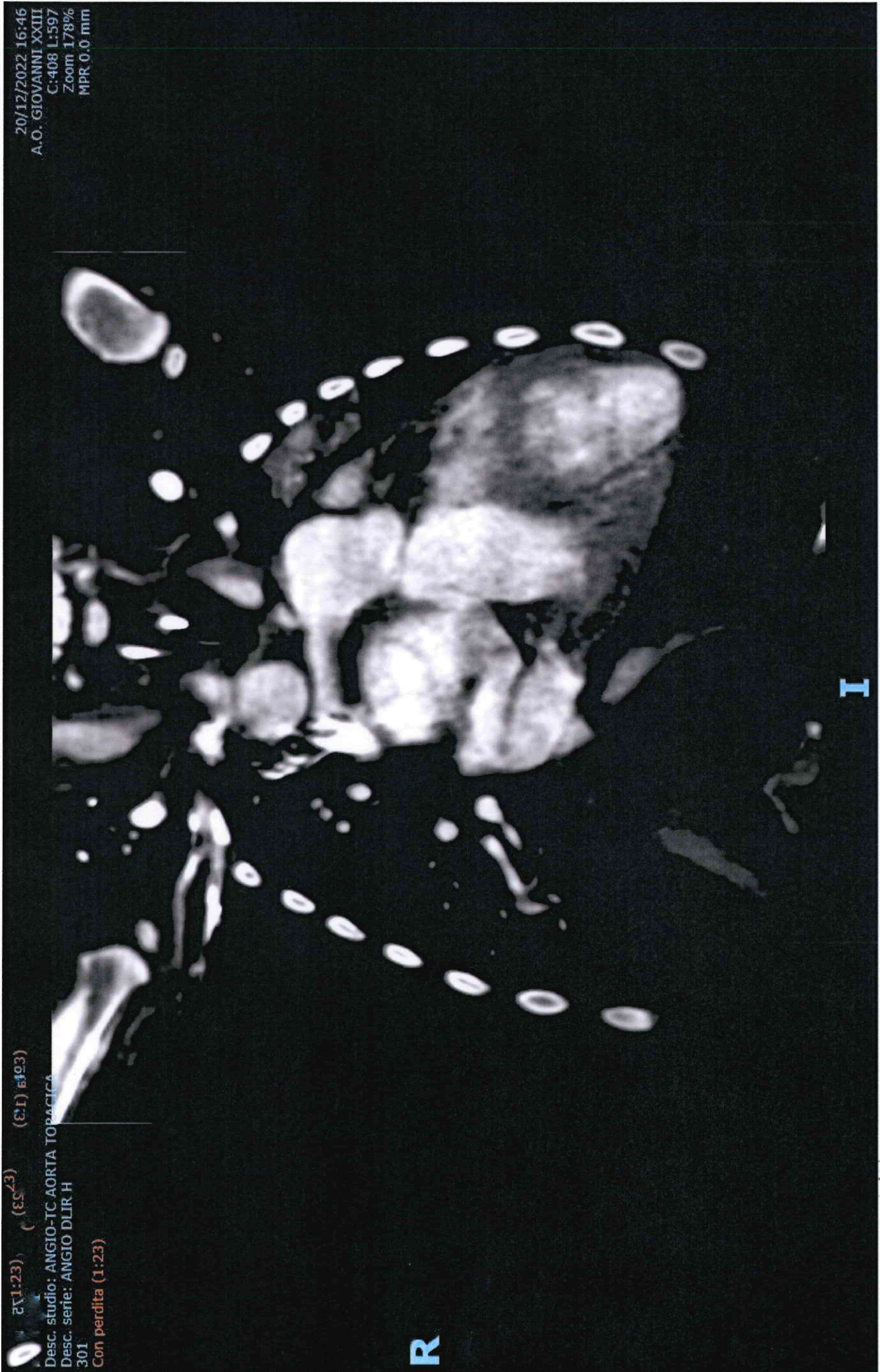
I

2.

[Handwritten signature]



[Handwritten signature]

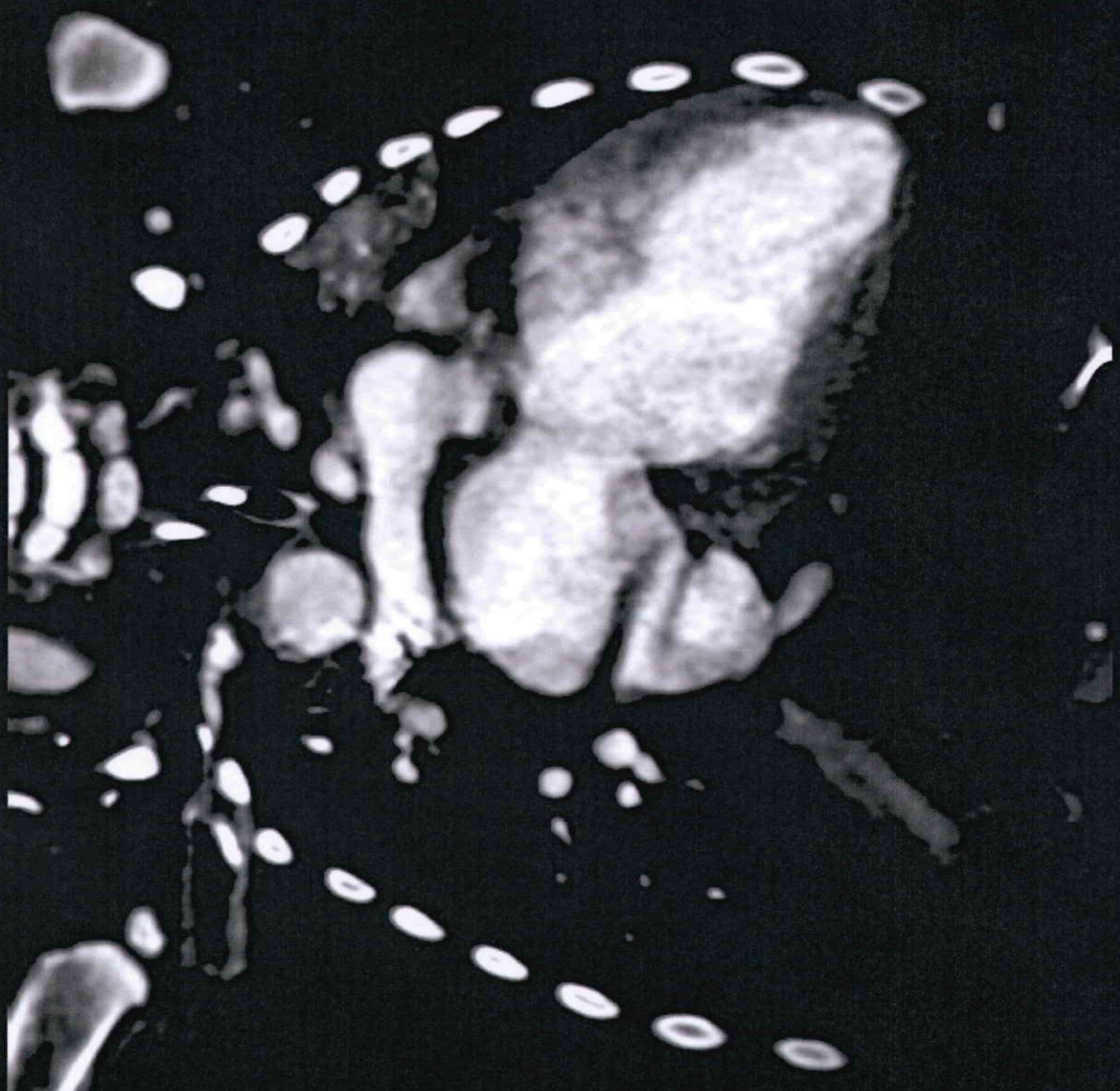


4.

Handwritten signature and initials in the bottom right corner of the page.

20/12/2022 16:46
A.O. GIOVANNI XXIII
C:408 L:597
Zoom 178%
MPR 0.0 mm

di
ua, F
fibrosua, F
Keua, F
125:1) sfb
Res. Ic
Desc. studio: ANGIO-TC AORTA TORACICA
Desc. serie: ANGIO DLIR H
301
Con perdita (1,24)



R

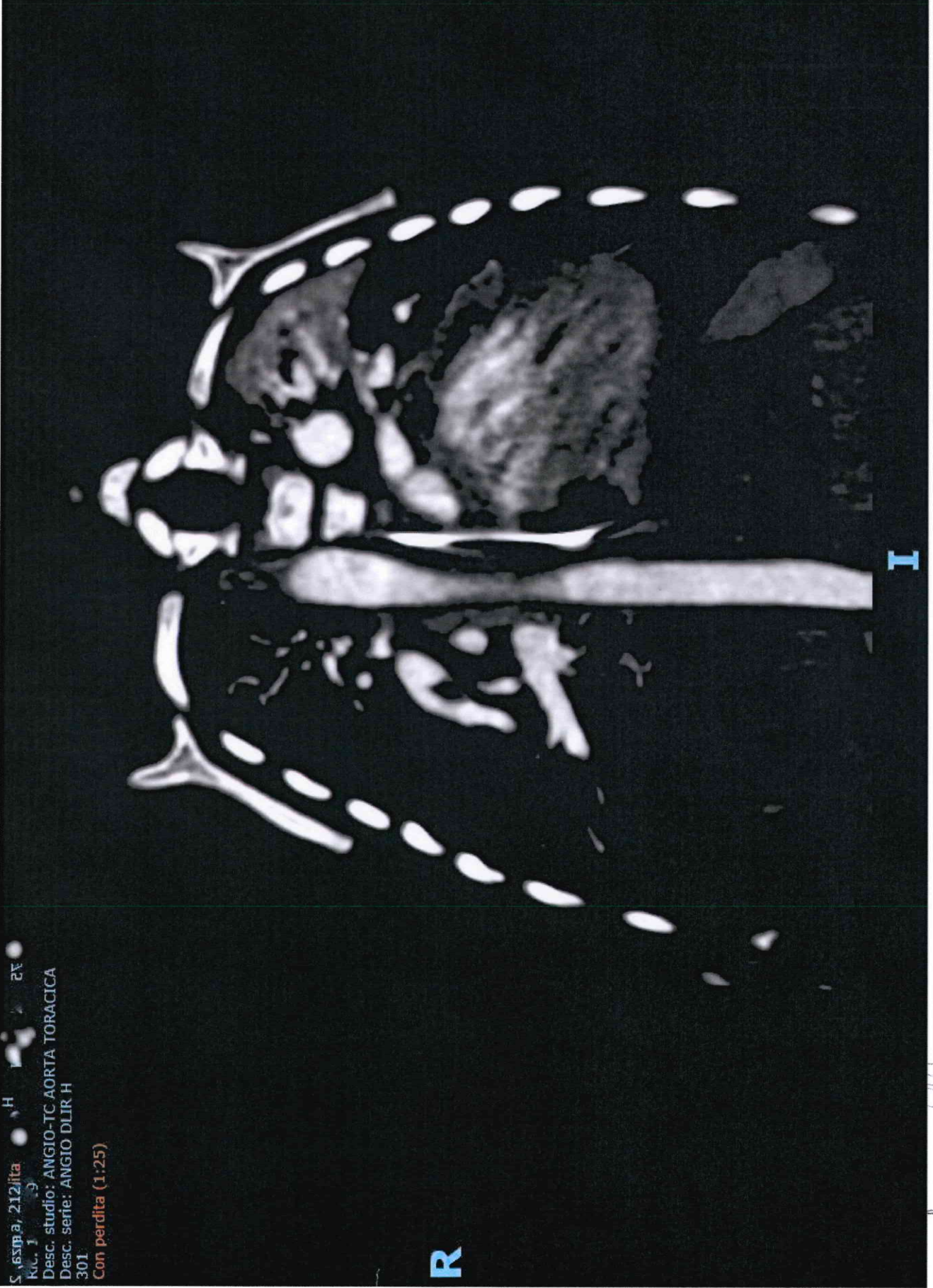
I

5.

Handwritten signatures and initials:
A large, stylized signature.
A smaller signature below it.
A signature below that.
A signature below that.
A signature below that.
A signature below that.

S. 6519a, 212jita H 2V
 R.C. 1 3
 Desc. studio: ANGIO-TC AORTA TORACICA
 Desc. serie: ANGIO DLIR H
 301
 Con perdita (1:25)

20/12/2022 16:46
 A.O. GIOVANNI XXIII
 C:408 L:597
 Zoom 178%
 MPR 0.0 mm



A
 T
 (Handwritten signatures and markings)

6.

Coartazione aortica



[Handwritten signature]

Canale atrio ventricolare



Tetralogia di Fallot

